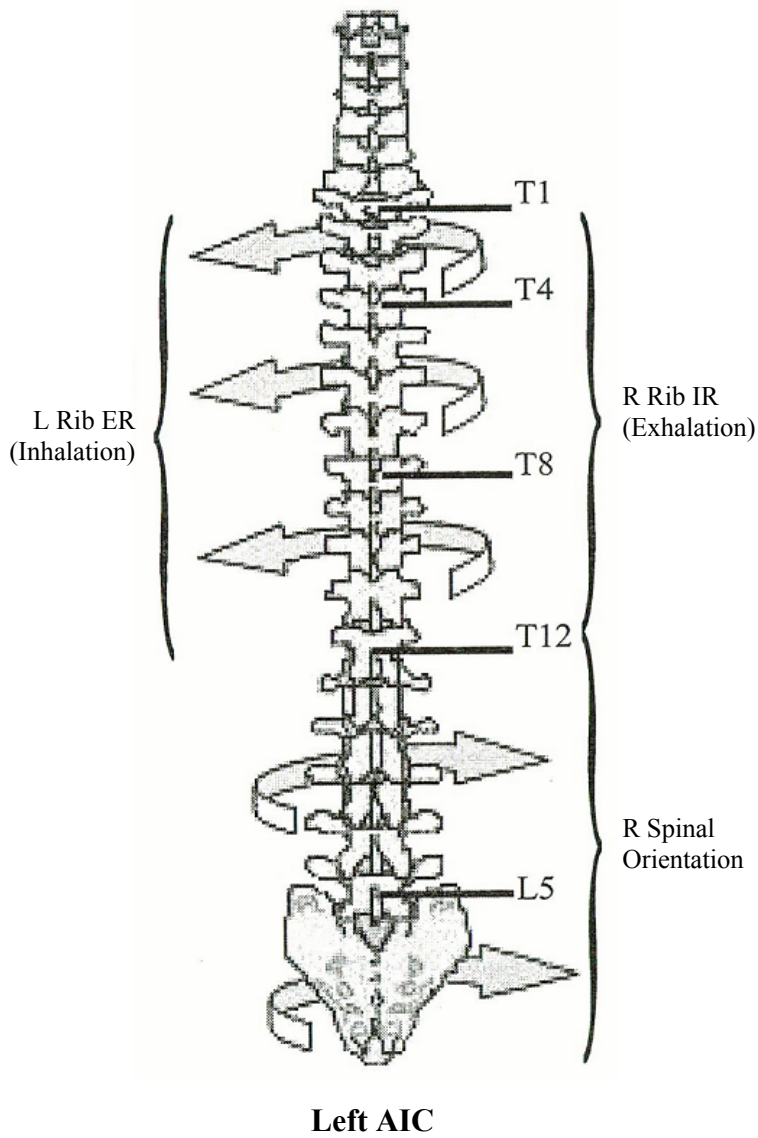


# The Influence of Thoracic Airflow and Rib Rotation on Transverse Spine Position

*Typical Right BC*



*Superior T4 Syndrome*

