

In 1955, Cooperman and Willard noted that the horizontal plane (HIP) through the hamular notches (H) and the incisal canal (IP) defined the basal bone of the maxilla on which develops the alveolar bone that supports the erupting teeth thus setting the natural occlusal plane.

We also understand from the work of Horvath that the natural occlusal plane will be corrupted if the airway is restricted. This occurs in association with a tongue thrust swallow due to lack of oral space. The tongue thrust impedes tooth eruption in the presence of forward head posture aimed at aiding the restricted respiration (Figure 1).

It will be noted that the posterior extension of the HIP plane bisects the atlanto-occipital joint. The occlusal plane should bisect the atlantoaxial joint space as in the physiological occlusion shown in Figure 2. However, when tooth eruption is impeded in association with overclosure of the vertical dimension of occlusion as illustrated in the Class II, Div I situation of Figure 3 then the occlusal plane will not pass through the atlanto axial joint. Note that even though the tongue is thrust forwards between the incisors rather than reposing in the roof of the mouth it continues to impinge upon the airway which is only 2mm in diameter compared with the airway diameter of 12 mm at the level of the hyoid bone which lies at the space of the vertebral disc of vertebrae C3 to C4. In the Bimler Cephalometric tracing of a healthy occlusion, Figure 4, it should be observed that the occlusal plane forms a tangent to the Curve of Spee with its center at the centrum masticale from which a perpendicular dropped to the tangent of the occlusal plane bisects the long axis of the first premolar tooth. The Curve of Spee follows the lingual cusps and cinguli not the buccal cusps and incisal surface of the maxillary posterior and anterior teeth as well as the mid joint surface of the articular eminence of the temporomandibular joint.

The Curve of Spee is a sphere which also delineates the Curve of Wilson in the transverse plane (Figure 5). The Curves of Spee and Wilson are part of the same sphere with its center at the centrum masticale along the trajectory of the temporomandibular ligament which forms the axis of swing of the condyle and mandible as they arc forwards along the occlusion following the Curve of Spee. Note that in the ideal occlusion the temporomandibular ligament subtends an angle of thirty degrees to the HIP as it passes through the temporomandibular joint to reach the center of the motion of jaw function as defined by Guzay in his Quadrant theory (1955).

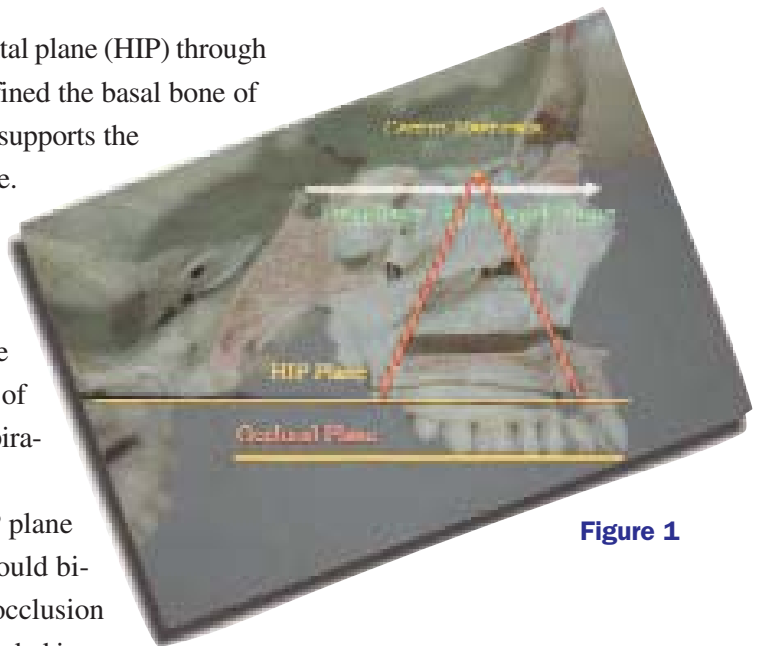


Figure 1

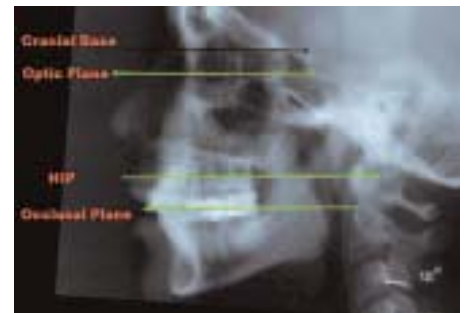

Figure 2

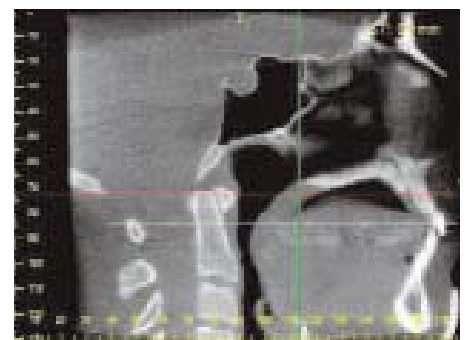


Figure 3

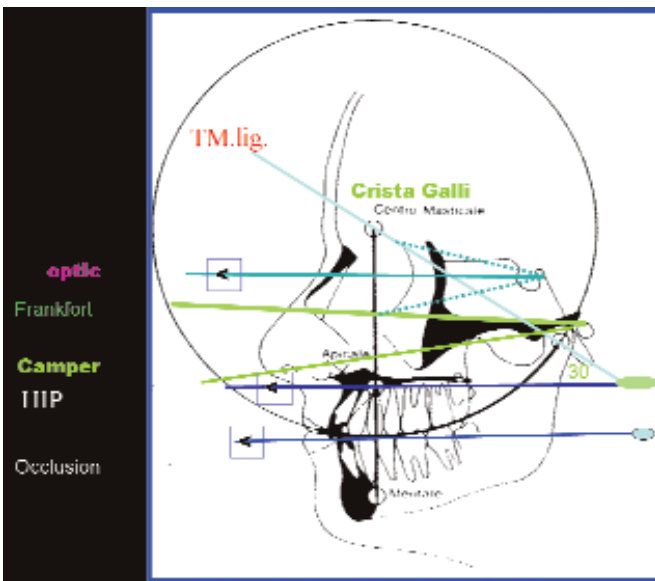


Figure 4

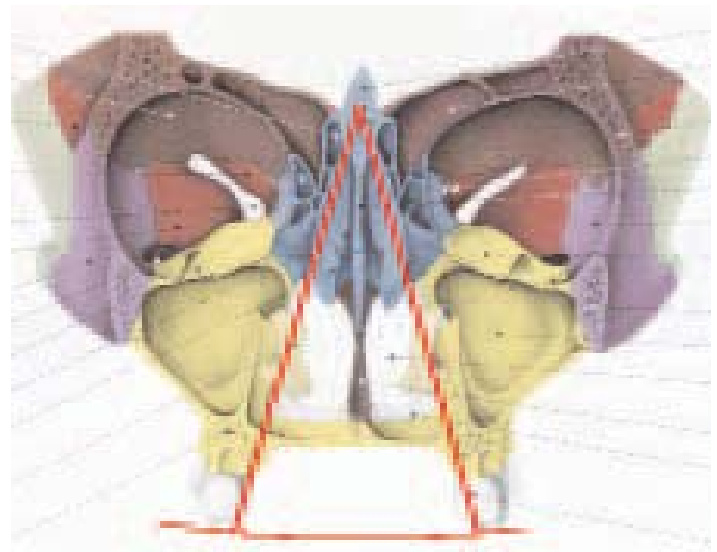


Figure 5

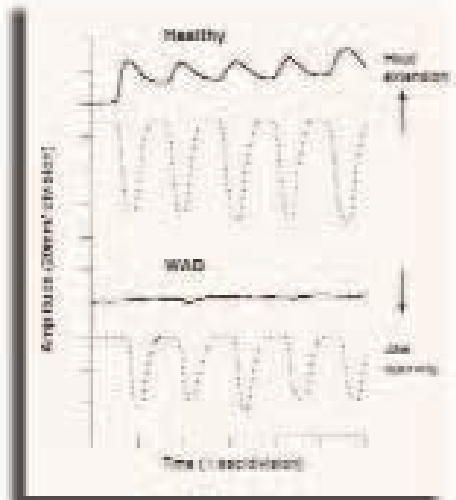


Figure 6

In Figure 4 we see that the tangent to the occlusal plane is parallel to the bipupillary plane and also the sphenoid base of the skull. Failure to understand the relationship of the maxillary lingual cusps and cinguli to the Curves of Spee and Wilson as well as to the occlusal plane, bipupillary plane, HIP and A/O joint has led to improper mounting of the maxillary dental casts on the horizontal stage of the occlusal evaluation (Stratos). Arbitrary use of the Fox Plane in violation of Wolff's law relating stress and strain in regards to the morphological and physiological properties of the occlusal system is known to lead to muscle fatigue.

In this context it is clear that there is reciprocity between the motion of the skull and neck both during maintained static posture as well as during function as in chewing. This is directed at maintaining posture and the horizontal gaze in the earth's gravitational field which, in failure, results in descending anti parallelism between head and shoulder plane when the bite and the skull base are not normal to the gravitational field.

Conversely parallelism of the head and shoulder plane tilt follows postural disturbances arising at any point below the atlanto axial joint and is designated ascending parallelism which secondarily unbalances the bite with resulting TMD. Figure 6 summarizes the findings of Zafar et al (2002) demonstrating reciprocity between the head posture and jaw function. Note that as the jaw opens the head extends posteriorly and vice versa in jaw closure. But it should also be noted that in Whiplash Disorder (WAD) decreased jaw movement accompanies decreased head neck motion. Only anterior posterior motion or pitch occurs at the A/O joint.



Figure 7

Only anterior posterior motion or pitch occurs at the A/O joint.

This would suggest that the shape of the mandibular condyle conforms to the shape of the occipital condyle and that relative retrusion of either of the TMJs

IACA 2008 Conference Presentations

Available on

Apple Video iPod

INCLUDES DR. BILL DICKERSON'S LAST LECTURE!



Enjoy Presentations from:

Dr. Joe Barton

Ms. Sherry Blair

Dr. Robert Brooks

Dr. Matt Bynum

Dr. Fred Calavassy

Dr. Anne-Maree Cole

Dr. Gary DeWood

Dr. Bill Dickerson

Mr. Tom Flick

Dr. Jay Gerber

Dr. Henry Gremillion

Dr. Sam Guirguis

Dr. William Hang

Mr. Ashley Johnson

Dr. Sam Kherani

Dr. Roger Levin

Dr. Greg Lutke

Dr. Art Mowery

Dr. Ross Nash

Dr. Gary Radz

Dr. Prabu Raman

Dr. Omer Reed

Dr. Larry Rosenthal

Dr. Michael Sernik

Dr. Norman Thomas

Mr. Chuck Wachendorfer

\$1,495 each
FULLY LOADED

order at www.theiaca.com or

866.NOW.IACA

while supplies last



will be combined with subluxation of the concomitant occipital condyle. Given that condylar remodeling is usually more severe on one of the TMJs, retrusion of the joints as in deriving CR should never be under taken. Thus relative retrusion of a TMJ condyle to centric relation not only produces retrusion of that joint but also subluxation medially of the ipsilateral occipital condyle.

In Figure 7 it will be noted that as anticipated the TMJ condyle and Occipital condyle impressions are perfectly conformed to each other. Note however that the medial pole of the TMJ condyle corresponds with the anterior pole of the occipital condyle. Thus as the skull slides directly anteriorly over the occipital condyles it traverses the temporomandibular joint from lateral to medial pole. The significance of this is that as the neck flexes anteriorly as in Forward Head Posture (FHP) the skull extends posteriorly in paradoxical fashion to maintain the horizontal gaze such that the jaw joint becomes posteriorly displaced into a Class II relationship and vice versa for Class III. The neutral position of the head and neck accordingly assumes Class I relationship of the jaws where the superior pole of the TMJ condyle centers on the intermediate zone of the TMJ disc. Therefore in conclusion the various skeleto-dental orthopedic classifications of the maxillo-mandibular relationship I, II and III are intimately related to body posture. Furthermore because of this interactive relationship of the occipital and mandibular temporomandibular joints subluxation of the atlanto-occipital joint is accompanied by displacement of the mandibular condyles and vice versa.

This was confirmed at LVI from studying the CAT Scan images of the cervical and temporomandibular condyles of 36 subjects suffering from TMD (Figure 8). It is noted that in this sample 30/36 subjects (83%) exhibit posteriorly pitched crania correspond to 54/72 (75%) posteriorly compressed temporomandibular joints of which 42/72 (80%) TMJs have retrodiscal compression on the right side and 24/36 (80%) of the A/Os are rolled to the right side. This relates to handedness of the subjects which are predominantly right dominant eye,

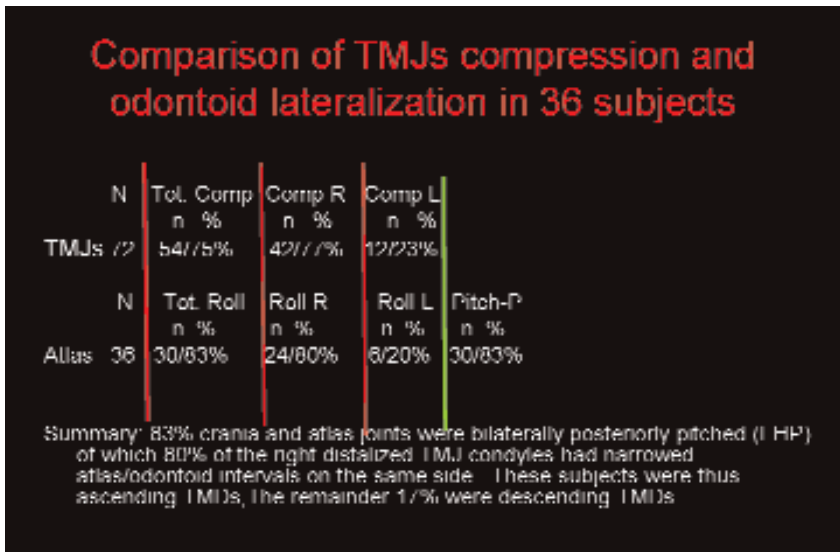


Figure 8

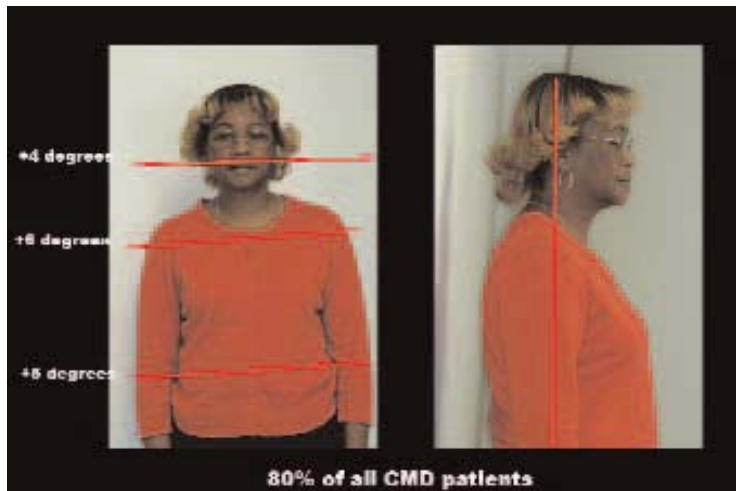

Figure 9

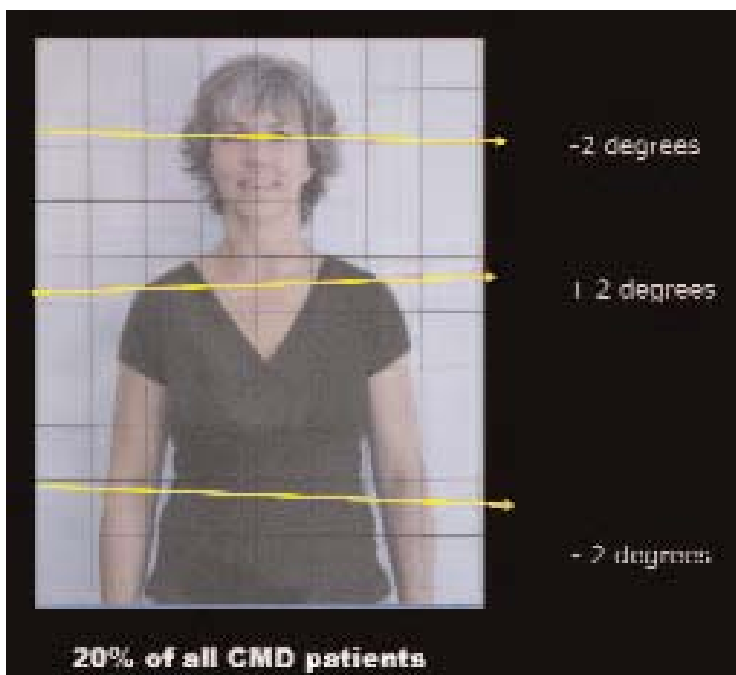


Figure 10

Neuromuscular Dentistry Powered by the K7

Dentists worldwide are discovering the science and the benefits of Neuromuscular Dentistry with Myotronics K7 technology.

Evaluate and successfully treat TMD, restorative and cosmetic cases with reliable, reproducible clinical data.

What Successful Dentists Have To Say



"Since incorporating Neuromuscular Dentistry and Myotronics instrumentation into my practice, my entire perspective of my diagnostic and clinical skills has changed. I now have the ability to measure, record, analyze, and store physiologic data and anatomic function to better provide predictable comprehensive dentistry."

JOSEPH BARTON, DMD, JACKSONVILLE, FL

"Nothing in this life beats the feeling that you truly helped make a positive difference in the life of another human being. Helping people that have suffered with the pain of TMD for years and even decades reclaim their lives is the ultimate. There is absolutely no way that I could provide this level of care without the K7 instrumentation."

PRABU RAMAN, DDS, KANSAS CITY, MO



"Without the K7 system and J5 Myomonitor, I would never have achieved the TMD treatment success that my patients now experience. The equipment is easy to employ in a clinical setting and delivers objective data and very accurate measurements."

ALLAN WINCHAR, DMD, WINNIPEG, MANITOBA

For complete details visit our website at myotronics.com



MYOTRONICS
Helping Build the Perfect Bite



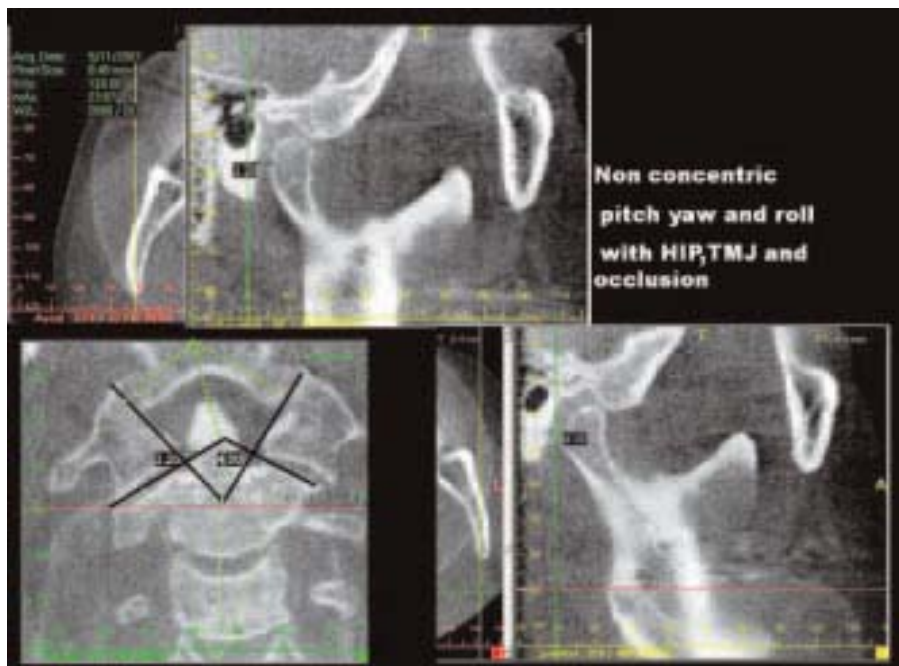


Figure 11

while in the descending the abnormal bite spreads downwards to lead to postural compensations. These postural compensations arise from proprioceptor feed to the labyrinth balance organ in the inner ear with relay to the brainstem vestibular nucleus. Importantly there are major connections from the jaw and dental receptors to signal occlusal deviations to the same region of the brain

hand and side chewers. Thus 80% of subjects have posteriorly pitched skulls as in FHP with roll to the right. This number corresponds to the majority having an ascending body posture with parallelism of the head, neck and head planes (approximately 80%, Figure 9) while 20% are descending postures with antiparallelism of the three planes (Figure 10).

The descending types have primary TMD signs and symptoms which affects the posture rostro-caudally from above down. In the ascending type the body imbalance spreads upwards to affect the bite

known as the mesencephalic nucleus of the fifth nerve which has the only example of first order neurons entering the brain by a process known as neurobiotaxis. Such is the importance of the bite to total body neurophysiology. But the question emerges where does the ascending mechanism begin and the descending mechanism end. Is it from a functionally short leg or from the rolled atlanto axial joints? We do know that the cervical tonic receptors play a significant role but it is not clearly understood how this relates to the important mesencephalic trigeminal nucleus to which proprioceptor information is relayed. This led us to examine the changes that occur in the cervical changes that accompany bite changes.

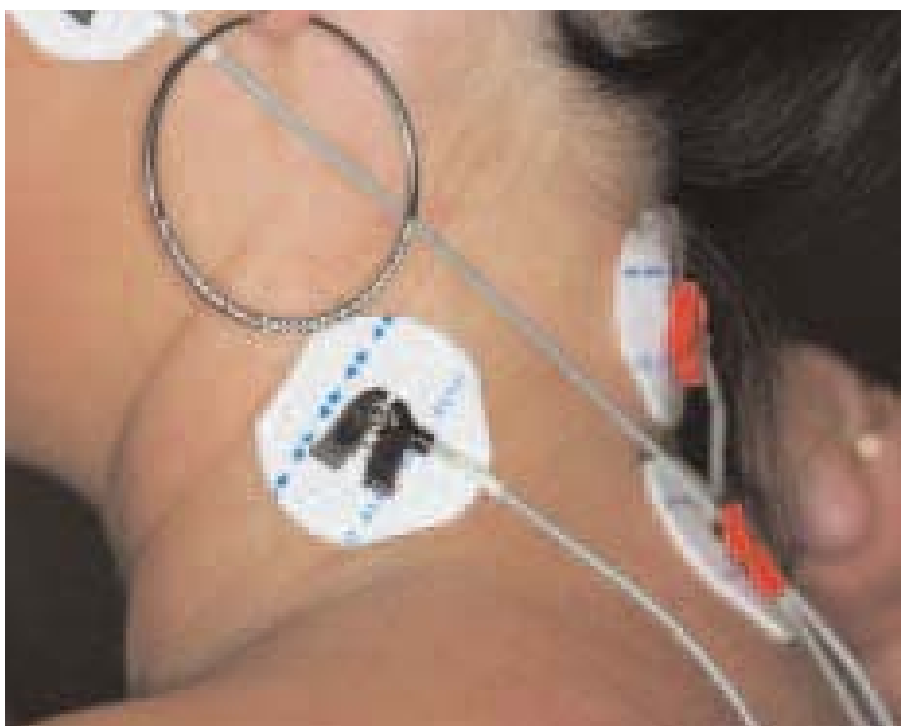

Figure 12

Figure 11 shows the CAT Scan image through the jaw joints and the upper cervical complex in known TMD (36) patients prior to correction of the occlusion by removable/fixed prostheses as in the rehabilitation of the edentulous and dentate patients respectively. It will be noted that the instantaneous axes of the

upper cervical complex are non concentric. Similarly the jaw joints are more compressed on the right side (3.2mm) corresponding to the decreased interval between the odontoid process and the right atlas (3.2mm) which is subluxed towards the left side. This correlation was demonstrated for all subjects although the measurements may vary somewhat dependent upon the degree of TM joint remodeling.

Following TENS relaxation of the neck and jaw musculature by antidromic activation and hyperpolarization of the trigeminal and cervical alpha and gamma motoneurons (Figures 12 and 13) of the fifth and eleventh nerves. The post relaxation ICat images of the cervical vertebrae (Figure 14) reveal concentricity of the atlanto-occipital and atlanto axial joints which line up with the midline of the vertebral column. In particular it will be noted that the instantaneous center for the atlanto axial joint is found centered at the intervertebral disc between C3 and C4 in the post TENS relaxed trigeminal and cervical musculature. The disc between C3 and C4 is found at the level of the hyoid bone which gives origin and insertion to the jaw openers and hence the anterior neck alignment which is markedly displaced in the pre TENS condition, Figure 11, indicative of an ascending effect on skull and TMJ alignment. The pre and post TENS ICats of the jaw joints, Figures 15 and 16, reveal the TMJ condylar posterior displacement prior to TENS (Scan 15) and the post TENS change in jaw joint position analogous with the subluxation of A/O and their correction following TENS.

In conclusion it has been clearly demonstrated that the correction of both the cervical and TMJ posture are essential to successful treatment of both ascending and descending TMD. It has also been shown that antidromic

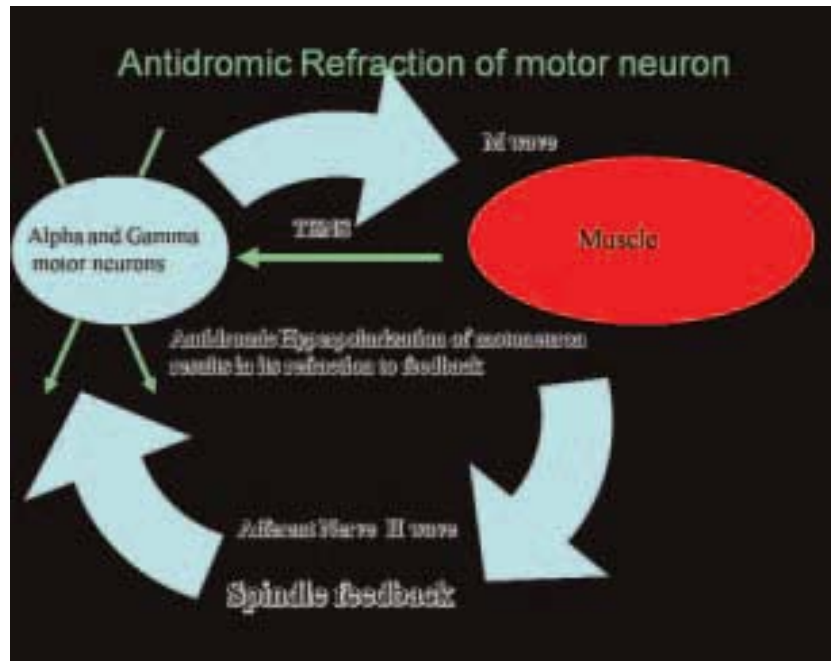


Figure 13

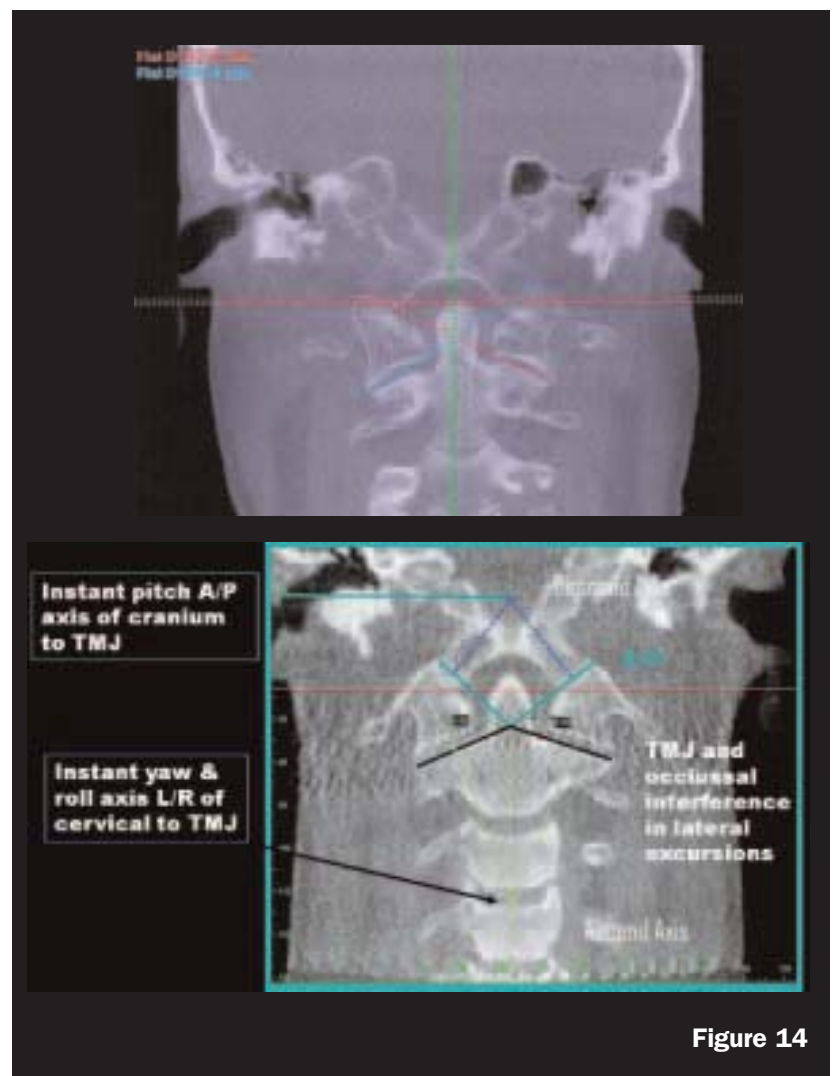


Figure 14

neural stimulation of the motoneurons to the trigeminal and spinal accessory nerves play a significant role by rendering the alpha and gamma motoneurons refractory to proprioceptor feedback allowing the muscles of the neck and jaw to assume a physiological relaxed muscle length. It is also shown that the site at which a descending TMD results is from muscle hyperactivity in the cervical extensor muscles of the cranium such as suboccipital muscles and trapezius muscles. On the other hand the ascending mechanism is located at levels below C3 to C4 levels which is the position of the hyoid bone that acts as a fulcrum for the jaw openers and cervical flexion of the cervical vertebrae.

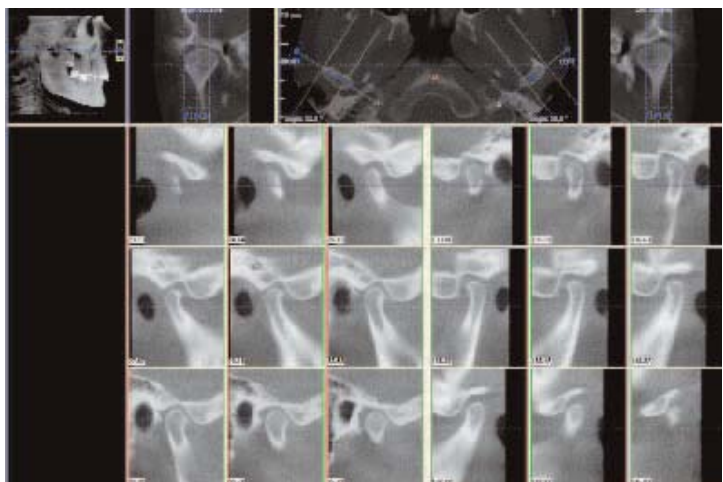


Figure 15

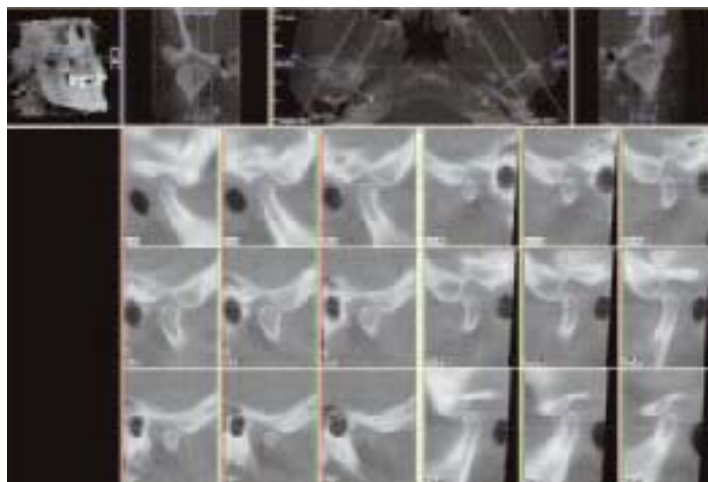



Figure 16



Norman Thomas graduated as a Doctor of Dental Surgery with honors and double Gold Medals in 1957. Dr. Thomas was awarded a Nuffield Fellowship (Oxford) to complete an honors degree in medical sciences in 1960. Between 1960 and 1974, he pursued residency and research programs at the Bristol Royal Infirmary, The Royal College of Surgeons of England, the Medical College of Virginia, and the University of Alberta, where he is now Professor Emeritus.

From 1970 to 2002, Dr. Thomas served on the Medical Research Council of Canada, the National Institute of Health, USA, and the Canadian Dental Association, gaining a Certificate of Merit from the latter and several Fellowships in medical sciences and dentistry. He is a Life Member of the Alberta Dental Association and retired from dental practice in 2002. In 1998, he was appointed Chancellor of the International College of Head and Neck Orthopedics and, in that capacity, has lectured in the U.S., Europe, Australia, and Asia. He was awarded a Ph.D. degree in Oral Medicine for research on the process and mechanism of tooth eruption.

2009 LVI Courses featuring Norman Thomas include:

- CORE I, II, IV, VI
- Anatomy and Physiology
- Rehabilitation of the Edentulous Patient
- Scan Interpretation
- TMD - Developmental Diagnosis